


PRESENTING CLINICAL SIGNS

History: Previously diagnosed with stage B1 degenerative valve disease (most recent echo in March 2022). Grade 4/6 murmur.

DATE

10/20/22

ECHOCARDIOGRAPHIC FINDINGS

2D, M-mode, and Doppler study.

PERFORMED BY:

Tom McNeill

There is mild left atrial dilation. The mitral valve leaflets are thickened and exhibit systolic prolapse. A mild to moderate jet of eccentric mitral regurgitation is present. There is mild left ventricular dilation. Left ventricular systolic function is normal. The aorta and aortic valve are normal. Right atrial and right ventricular dimensions are normal. The tricuspid valve is normal. The pulmonary artery and pulmonic valve are normal. No pericardial effusion or cardiac masses are seen.

INTERPRETED BY

 Keith Blass, DVM,
 MS, DACVIM
 (Cardiology)

 LA - 31.6 mm
 LVIDd - 31.7 mm
 LVIDd - 18.5 mm
 FS - 41.6%
 RA - 17.5 mm
 LVOT - 1.53 m/s
 RVOT - 0.83 m/s

PATIENT

Rizzo Andrews

ASSESSMENT/RECOMMENDATIONS

Degenerative mitral valve disease

SPECIES

Canine

This examination demonstrates some progression of Rizzo's mitral valve disease, as he now has mild secondary dilation of both his left atrium and left ventricle. As only mild left heart chamber dilation is present, Rizzo's current risk for the development of clinical signs secondary to his disease, such as coughing, exercise intolerance, syncope, and labored breathing, appears to be relatively low, though careful monitoring for these signs is recommended going forward.

BREED

Chihuahua Mix

I recommend starting Rizzo on pimobendan (1.25 mg BID), as this medication should help to slow the progression of his mitral valve disease.

SEX

A recheck echocardiogram is recommended in ~9 months. Thoracic radiographs are recommended if Rizzo experiences respiratory clinical signs.

MN
AGE

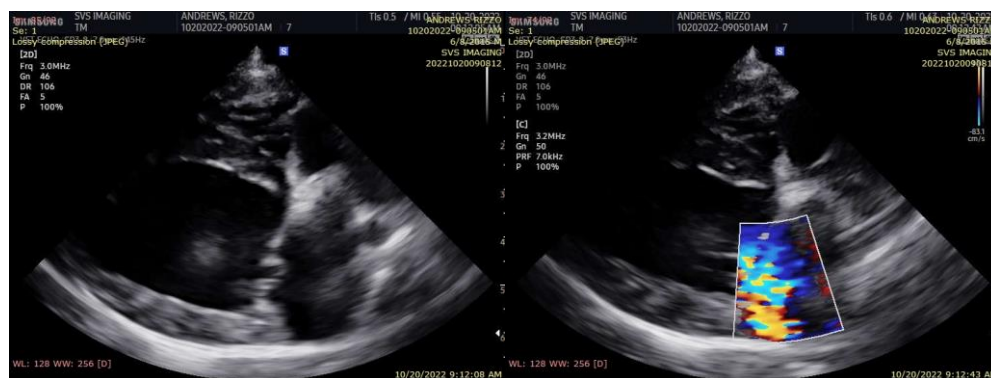9 y

WEIGHT

12 lb

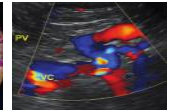
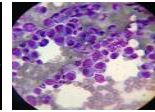
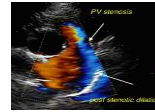
HOSPITAL NAME

SVS Imaging CT


REFERRING VET

Dr. Wolf

The information and recommendations provided are based on the images presented by the referring veterinarian. No evaluation can be communicated regarding pathology that was not



visible in the image/video clips provided.

DATE

10/20/22

Thank you for this referral. If the clinical or image interpretation does not parallel your findings or if I can be of any further assistance please contact me.

PERFORMED BY:

Tom McNeill

Keith Blass, DVM, MS, DACVIM (Cardiology)
KeithBlass@gmail.com
631-804-5754

INTERPRETED BY

Keith Blass, DVM,
MS, DACVIM
(Cardiology)

PATIENT

Rizzo Andrews

SPECIES

Canine

BREED

Chihuahua Mix

SEX

MN

AGE

9 y

WEIGHT

12 lb

HOSPITAL NAME

SVS Imaging CT

REFERRING VET

Dr. Wolf